

Technical notes & surgical techniques

Safety and efficacy of navigated trocarless pedicle screw placement: Technical note



Giuseppe Emmanuele Umana^{a,b,*}, Gianluca Scalia^g, Chiara Perrone^a, Francesco Garaci^{d,e},
Andrea Pagano^a, Adolfo De Luna^a, Salvatore Cicero^b, Massimiliano Visocchi^f,
Giovanni Federico Nicoletti^g, Antonino Germanò^c, Pierpaolo Lunardi^a

^a Department of Neurosurgery, Tor Vergata University Hospital, Rome, Italy

^b Department of Neurosurgery, Cannizzaro Hospital, Trauma Center, Gamma Knife Center, Catania, Italy

^c Division of Neurosurgery, Department of Biomedical and Dental Sciences and Morpho-Functional Imaging, University of Messina, Messina, Italy

^d Neuroradiology Unit, University of Rome Tor Vergata, Rome, Italy

^e San Raffaele Cassino, FR, Italy

^f Craniovertebral Junction Operative Unit and Master CVJ Surgical Approach Research Center, Institute of Neurosurgery, Policlinic "A. Gemelli", Catholic University, Rome, Italy

^g Department of Neurosurgery, Highly Specialized Hospital of National Importance "Garibaldi", Catania, Italy

ARTICLE INFO

Keywords:

Lumbar spine
Pedicle screws
Mispositioning
One-step

ABSTRACT

Background: Standard open techniques for pedicle screws placement require extensive tissue dissection for optimal screw trajectory. Furthermore, they have been associated with extensive blood loss, long hospital stays and, consequently, significant costs.

Objective: To describe a percutaneous pedicle screw fixation performed with a novel navigated "one-step" system, underlining the safety and effectiveness of such technique.

Methods: During a 43-month period, 43 patients with 230 pedicle screws were evaluated. Percutaneous pedicle screw fixation was performed in the lumbosacral region in 5 patients (12%), lumbar region in 13 (30%), thoracolumbar region in 21 (49%) and thoracic region in 4 (9%). We have compared the accuracy rates of screw placement achieved with percutaneous pedicle screw fixation using fluoroscopy, and neuronavigated percutaneous pedicle screw fixation using an innovative "one-step" technique.

Results: Statistical differences in screws placement accuracy between the group A and B were evaluated by Fisher exact test. The accuracy rate of pedicle screws placement in group with the intraoperative navigation system was higher than that of the group with fluoroscopy ($P = 0.04$). There was no hardware failure except 3 screws of Group A (1.3%) that pulled out few weeks after surgery. There were a total of 6 SAR (2.61%) and only 1 of them belonged to group B, without the need of revision surgery (0.61% out of the total neuronavigated stabilizations), while the other 5 represent 7.35% of the total screws placed with fluoroscopy. In our patient series the risk of mispositioning has been reduced by 14.95% with the use of the neuronavigation system, considering as malposition the set of IMP and SAR.

Conclusions: Percutaneous pedicle screw fixation with neuronavigated "one-step" technique represents a safe and effective tool in minimally invasive spine surgery that deserves a further investigation and widespread diffusion.

1. Introduction

During the last two decades, navigated surgical techniques have become increasingly important in spinal surgery, but only 11% of surgeons use them routinely [1]. Indeed, the widespread use of pre-operative CT navigation has reduced the number of incorrectly

positioned screws, but it has not yet erased it.

The authors evaluate the results achieved using neuronavigation, showing their experience with a novel "one-step" system which avoids the need of guidewires and trocars.

* Corresponding author at: Department of Neurosurgery, Cannizzaro Hospital, Trauma Center, Gamma Knife Center, Via Messina, 829, 95126 Catania, Italy.
E-mail address: umana.nch@gmail.com (G.E. Umana).

<https://doi.org/10.1016/j.inat.2020.100771>

Received 20 March 2020; Received in revised form 4 May 2020; Accepted 9 May 2020

2214-7519/© 2020 The Authors. Published by Elsevier B.V. This is an open access article under the CC BY-NC-ND license (<http://creativecommons.org/licenses/by-nc-nd/4.0/>).

Table 1
Demographic data of patients undergoing spinal stabilization surgery.

Patients' demographics	
Patients (n)	43
Screws (n)	230
Sex	
Males	21 (48.8%)
Females	22 (51.2%)
Age (years)	
Mean	59.19 years
Range	19–79 years
Diagnosis	
Trauma	26 (60.5%)
Degenerative conditions	11 (25.6%)
Osteoporotic fractures	2 (4.6%)
Spinal tumors	4 (9.3%)

2. Materials and methods

Between December 2014 and June 2018, a total of 43 consecutive patients underwent spinal stabilization surgery with pedicle screws and titanium rods placement [Table 1](#).

Pathologies associated to spinal instability and therefore needing stabilization surgery are grouped as follows: traumatic fractures (n = 26), degenerative conditions (n = 11), osteoporotic fractures (n = 2), spinal tumors (n = 4).

12 out of 43 consecutive patients underwent percutaneous stabilization with pedicle screws with standard fluoroscopy technique (Group A); 31 out of 43 patients underwent percutaneous stabilization with pedicle screws using the intraoperative navigation system (Group B). All medical data, including records and images, were retrospectively reviewed, and grouped by age, sex, diagnosis, number of fixation levels, eventual perioperative complications (e.g. screw mispositioning). [Table 2](#) summarizes the basic characteristics of patients undergoing fluoroscopy screw placement (Group A) and [Table 3](#) summarizes those with the navigation system (Group B).

2.1. Patient preparation

A pre-operative spine CT study is acquired—in prone position if tolerated—which must have the following characteristics to maximize the accuracy: volumetric scan (0.6 mm × 0.3 mm), 0.3 mm slice thickness, comprising entirely one or more metamers object of stabilization, including vertebral bodies, spinous and transverse processes; moreover, no reconstruction or bone algorithms are required.

2.2. Operative settings

Surgical instruments are equipped with a reference matrix and another one is secured on the spinous process of the reference level, which allows to acquire with decreasing accuracy the vertebra on which the reference star is fixed, the adjacent vertebrae one or two levels inferiorly and superiorly. Once this limit is exceeded, the accuracy is no longer adequate and other intraoperative points on the vertebra must be acquired. In some cases, such as fractures of the vertebral body with hyper-kyphosis, if the registration has been made at the level of the fracture, the accuracy is reduced to cranial levels compared to intraoperative registration of laminar points. Therefore, it could be necessary to acquire points also at the vertebra above the fracture. The tools are ready for navigation after a quick validation step, after few seconds. Real-time tool's visualization potentially improves accuracy of implant placement, thereby reducing the risk of mispositioning.

Table 2
Demographic data of patients with fluoroscopy-guided screw placement.

Group A	
Patients (n)	12
Screws (n)	68
Sex	6 (50%)
Females	6 (50%)
Males	
Age (years)	
Mean	58.2 years
Range	19–77 years
Diagnosis	
Trauma	6 (50%)
Degenerative conditions	2 (16.7%)
Osteoporotic fractures	1 (8.3%)
Spinal tumors	3 (25%)
Laminectomy	
Performed	7 (58.3%)
Not performed	5 (41.7%)
Surgical Time (hours)	
Mean	4.42 h
Accuracy	
AP	57 (83.2%)
BMP	3 (4.4%)
IMP	3 (4.4%)
SAR	5 (7.3%)
Level	
Thoracic	2 (17%)
Thoraco-lumbar	6 (50%)
Lumbar	3 (25%)
Lumbo-sacral	1 (8%)
Fixed level	
Two	7 (58.3%)
Three	1 (8.3%)
Four	3 (25%)
Five	1 (8.3%)

2.3. C-ARM and intraoperative X-ray use

During the surgical procedure, X-rays are used to obtain antero-posterior (AP) and latero-lateral (LL) fluoroscopic images, especially in order to position the reference star on the correct vertebral level, to periodically test the correct positioning of the screws, and finally to evaluate their correct allocation before finalizing the system.

2.4. Surgical technique

The patient is placed in prone position on a radiolucent table. A spinal needle is inserted into the spinous process to identify the exact level on which the reference points will be recorded intraoperatively. A latero-lateral fluoroscopic image is used to detect the correct positioning of the needle. A longitudinal skin incision (about 3–4 cm) and bilateral muscular skeletonization of the laminae of a single vertebra are performed, which represents the object of the registration of the intraoperative points for the positioning of the reference matrix for navigation. In our experience we acquire the laminar points as provided for open navigation, even if in fact we will perform a percutaneous navigation and surgery using mini-open approach. The main advantage of registering with laminar points is the immediate evaluation of the navigation accuracy, since it is possible to directly check the correspondence between the pointer, the images displayed by the navigation device and the bone reference structures as the articular processes, the laminae, the spinous processes and the pedicles.

It is mandatory to rigidly fix the reference arch onto the spinous process of the vertebra that has been elected to navigate, to ensure that the arch does not move relatively to the patient's vertebral spine [Fig. 1](#).

Table 3
Demographic data of patients with neuronavigated screw placement.

Group B	
Patients (n)	31
Screws (n)	162
Sex	
Females	16 (51.6%)
Males	15 (48.4%)
Age (years)	
Mean	59.6 years
Range	30–79 years
Diagnosis	
Trauma	20 (64.52%)
Degenerative conditions	9 (29.03%)
Osteoporotic fractures	1 (3.23%)
Spinal tumors	1 (3.23%)
Laminectomy	
Performed	9 (29.03%)
Not performed	22 (70.96%)
Surgical Time (hours)	
Mean	3.42 h
Accuracy	
AP	149 (91.97%)
BMP	6 (3.7%)
IMP	6 (3.7%)
SAR	1 (0.6%)
Level	
Thoracic	2 (6.45%)
Thoraco-lumbar	15 (48.4%)
Lumbar	10 (32.3%)
Lumbo-sacral	4 (12.9%)
Fixed level	
Two	17 (54.84%)
Three	8 (25.81%)
Four	6 (19.35%)
Five	0 (0%)

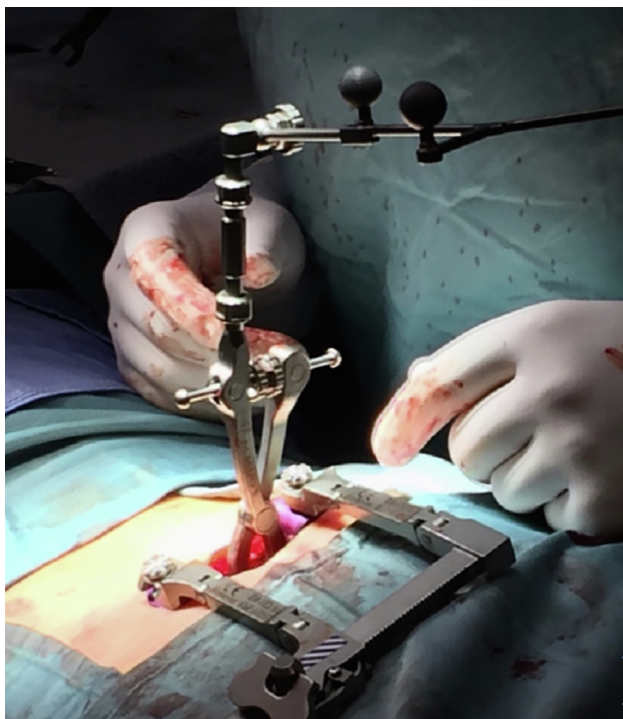

Fig. 1. Positioning of the reference arch onto the spinous process of the vertebra.

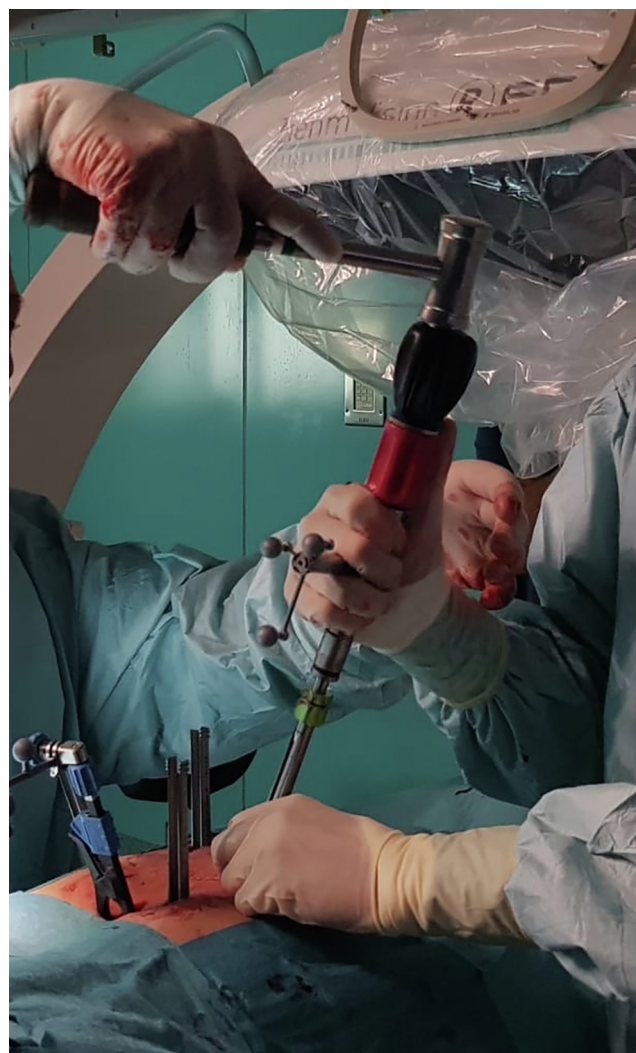

Fig. 2. VIPER PRIME™ “one-step” system (DePuy Synthes) instruments.

After positioning, the registration step is completed with acquisition of the intraoperative points (spinous process - right lamina - left lamina). About 20 points are necessary for the neuronavigator to recognize the position of the reference star related to the patient's anatomy. We proceed to a cutaneous paramedian incision of about 2 cm through which the screw using a navigated screwdriver will be inserted into the pedicle of interest without the need of time-consuming trocar's passages, because of the screw tip that is aggressive. **Fig. 2** Due to navigation, it is possible to choose to customize the treatment and to apply larger screws **Fig. 3**. The validity of the system is controlled intermittently by positioning a probe on an exact anatomical reference point. Afterwards, fixation procedure can be completed. The accuracy of the placement of the pedicle screws is assessed by a neuroradiologist with a postoperative CT scan, unlike many other centers that rely on postoperative X-ray, with the risk of underestimating the degree of malposition. In fact, in general, low rates of mispositioning exist in the literature: Hicks et al. in their systematic review have found a 4.2% rate of mispositioned pedicle screws [2]. The pedicle violations were classified according to an established classification system [3].

Therefore, we used a classification that divides each screw for each patient as follows:

1. screw at risk (SAR): medially protruding screws for more than 4 mm, or screws that laterally or anteriorly are in contact with (distance < 1 mm between the tip of the screw and the organ)

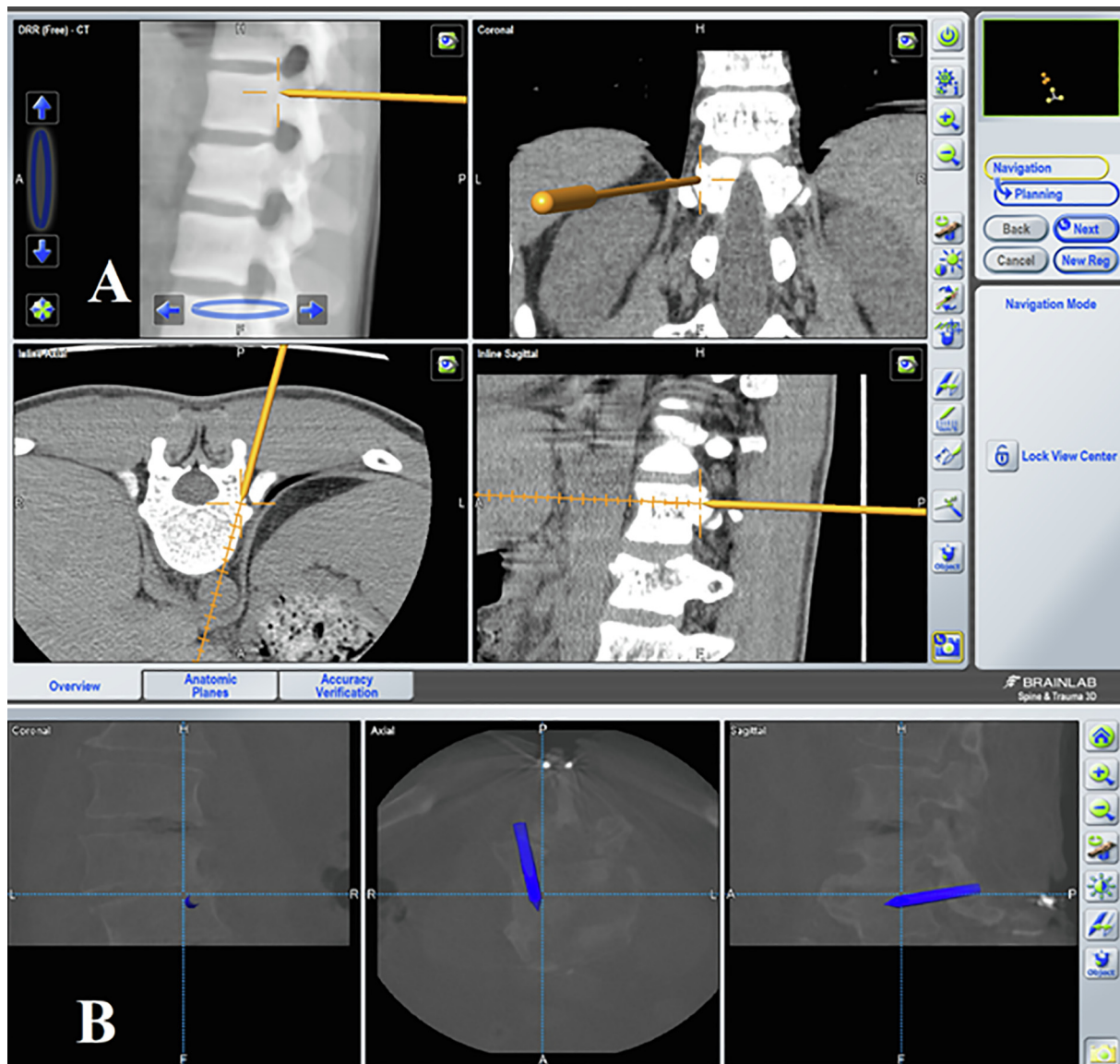


Fig. 3. Sagittal, coronal, and axial CT scan reconstruction. (A) Screw's virtual extension in red as a roadmap, the trajectory of the trocar in yellow (B).

anatomical structures such as the aorta, the trachea and the esophagus.

2. indeterminate misplacement (IMP): the screws protrude medially between 2 and 4 mm or are laterally or anteriorly adjacent (distance > 1–2 mm between the tip of the screw and the organ) to the anatomical structures.
3. benign misplacement (BMP): screws that get past the cortical wall but do not put any structure at risk.
4. accurately placed (AP): screws completely contained in the pedicle.

3. Results

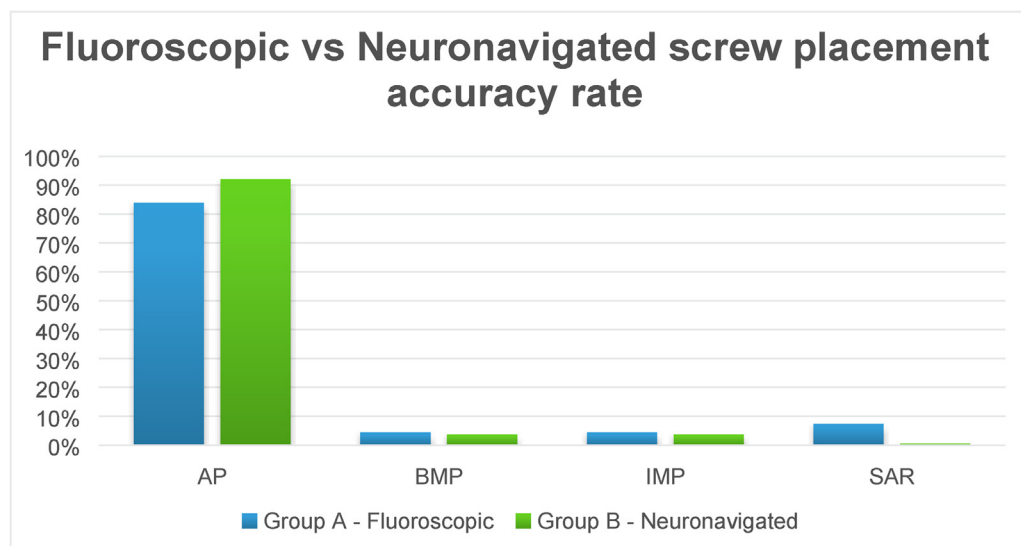
During a 43-month period, 230 pedicle screws were evaluated in 43 patients. Spinal stabilization surgery was performed in the lumbosacral region in 5 patients (12%), lumbar region in 13 patients (30%), thoraco-lumbar region in 21 patients (49%) and thoracic region in 4 patients (9%). There was no hardware failure except 3 screws of Group A (1.3%) that pulled out few weeks after surgery, There were a total of 6 SAR (2.61%) and only 1 of them belonged to group B, without the need of revision surgery (0.61% out of the total neuronavigated stabilizations), while the other 5 represent 7.35% of the total screws placed

with fluoroscopy. In our patient series the risk of mispositioning has been reduced by 14.95% with the use of the neuronavigation system, considering as malposition the set of IMP and SAR. Table 4 Of notice, the worse results of group A is related mainly to a single patient that presented several mispositioned screws, so this data is probably over estimated.

Statistical differences in screws placement accuracy between the group A and B were evaluated by Fisher exact test. The accuracy rate of pedicle screws placement in group with the intraoperative navigation system was higher than that of the group with fluoroscopy ($P = 0.04$).

We found that in the lumbar region the accuracy rates are very similar between the two groups, and this is justified by the fact that the insertion of pedicle screws in this region is easier for surgeons than in the thoracic one, in which the peduncles are narrower. It is precisely in the thoracic region, conversely, that we found a clear difference in accuracy in favour of group B. With fluoroscopy, out of the 30 screws placed in the thoracic region, only 20 were accurately positioned (66.67%) Table 5; with neuronavigator, out of the 56 screws placed in the thoracic region, 46 were carefully positioned (82.14%) Table 6. Although the two case-control arms are not perfectly balanced for the number of patients (note that the number of screws placed with a

Table 4
Histogram with grouped columns that highlights the accuracy rates of the screw positioning in group A with fluoroscopy and in group B with neuronavigator.



neuronavigator is more than double compared to the one with fluoroscopy), the rates have been standardized and reported as a percentage; therefore, there is a substantial difference of 15.47% between the two groups, which allows us to affirm the higher accuracy in the neuronavigator’s group, at least in the thoracic region.

No dural defects or neurological deficits occurred after surgery in both groups. For 3 patients of group A the indication of reoperation was set: 2 patients for pull-out of one screw and 1 patient for screws at risk of vascular injury. One patient did not consent to the reoperation while the other two’s stabilization systems were successfully revised. There was no need for reoperation among patients in group B. On the other hand, it also needs to be also reported that, radiological parallelism and symmetry of the screws as demonstrated with postoperative X-Rays spine study appears to be more evident in Group A patients compared to the Group B ones.

4. Discussion

Incorrect positioning of the screw can cause nerve and dural injury, this causes persistent pain, neurological deficits, cerebrospinal fluid leakage (CSF), infections and increased costs [4]. So, accuracy, radiation exposure, cost effectiveness the choice of the instrumentation system and the learning curve seems to strongly interact with spine instrumentation surgery.

4.1. Accuracy

Standard open techniques for pedicle screws placement require extensive tissue dissection to expose entry points and provide lateral orientation for optimal screw trajectory. Furthermore, they have been associated with extensive blood loss, long hospital stays and, consequently, significant costs [5].

Our approach in both groups was percutaneous, which compared with open surgery has brought the known several advantages. With

fluoroscopy, the rate of mispositioned screws still settles between 12% and 21% [6].

In our hands, navigation provides more accuracy in positioning pedicle screws than the conventional method, especially in the thoracic region, while remaining in line with literature.

We can also note that increasing the number of screws placed with the neuronavigator increases accuracy, and this finding brings us to another key point of the use of the neuronavigator: the learning curve.

4.2. Radiation exposure

Occupational radiation exposure may lead to high cumulative doses throughout life. Although an active spinal surgeon may remain below the annual occupational exposure limits with the reported radiation doses, any reduction thereof would be desirable. This is of fundamental importance since the long-term effects of chronic low-grade exposure are not yet established but would appear to increase the risk of certain types of cancer [7].

By using the navigation technique, radiation exposure was limited. On the other hand, by using the fluoroscopic technique, the surgical team was exposed during all the time of the procedure.

The surgeon’s radiation exposure has been measured by Villard with digital dosimeters placed at the level of the eye, chest, and dominant forearm. The cumulative doses were 25 against 270 μSv (P < 0.007) for the thorax; 17 against 96 μSv (P < 0.001) for the eye; and 15 against 106 μSv (P < 0.008) for the forearm in the navigated groups compared to those not navigated, respectively [8]. The radiation dose accumulated by the surgeon is significantly higher in the fluoroscopy group: this is therefore a further advantage that makes it reasonable to use the navigation whenever possible.

One of the limitations of our neuronavigator is the difference in accuracy between right and left: our neuronavigation system is more accurate in the placement of *trans*-pedicle screws on the right side. This could be explained by the fact that the neuronavigator is positioned on

Table 5
Accuracy rate of patients with fluoroscopy screw placement (Group A).

Level	AP	BMP	AP + BMP	IMP	SAR	IMP + SAR
Thoracic	20 (66.67%)	2 (6.67%)	22 (73.33%)	3 (10%)	5 (16.67%)	8 (26.67%)
Lumbar	33 (97.06%)	1 (2.94%)	34 (100%)	0 (0%)	0 (0%)	0 (0%)
Sacral	4 (100%)	0 (0%)	4 (100%)	0 (0%)	0 (0%)	0 (0%)

Table 6
Accuracy rate of patients with neuronavigated screw placement (Group B).

Level	AP	BMP	AP + BMP	IMP	SAR	IMP + SAR
Thoracic	46 (82.14%)	4 (7.14%)	50 (89.29%)	5 (8.93%)	1 (1.79%)	6 (10.71)
Lumbar	96 (96.97%)	2 (2.02%)	98 (98.99%)	1	0	1 (1.01%)
Sacral	7 (100%)	0 (0%)	7 (100%)	0 (0%)	0 (0%)	0 (0%)

Table 7
Accuracy rate of right neuronavigated screws.

Level	AP	BMP	AP + BMP	IMP	SAR	IMP + SAR
Thoracic	24 (85.71%)	2 (7.14%)	26 (92.96%)	1 (3.57%)	1 (3.57%)	2 (7.14%)
Lumbar	49 (100%)	0 (0%)	49 (100%)	0 (0%)	0 (0%)	0 (0%)
Sacral	3 (100%)	0 (0%)	3 (100%)	0 (0%)	0 (0%)	0 (0%)

Table 8
Accuracy rate of left neuronavigated screws.

Level	AP	BMP	AP + BMP	IMP	SAR	IMP + SAR
Thoracic	22 (78.57%)	2 (7.14%)	24 (78.57%)	4 (14.29%)	0 (0%)	4 (14.29%)
Lumbar	47 (94%)	2 (4%)	49 (98%)	1 (2%)	0 (0%)	1 (2%)
Sacral	4	0 (0%)	4 (100%)	0 (0%)	0 (0%)	0 (0%)

the right side of the operating table, therefore there is a potential increase in inaccuracy with the increase of the distance from the optical reader, as can be seen from the results of our series [Tables 7 and 8](#).

Finally, to be underlined that the use of intraoperative neuroradiological assessment as multi planar fluoroscopic images and intraoperative CT scan seem to further lower the residual inaccuracy related to preoperative TC assessment [\[9\]](#).

4.3. Cost effectiveness

The main disadvantage of the neuronavigation system is its high cost compared to previous conservative methods, but the multidisciplinary use (in every neurosurgical department a neuronavigation system for brain procedures is available) increases the probability of using the system and can therefore improve cost efficiency. In our opinion, the decrease of screws mispositioning rates, with the aid of the neuronavigation system, could reduce cost burden.

4.4. Percutaneous instrumentation device “one-step or trocarless”

In our experience, the use of trocarless navigation system represents a successful choice; it allows to best exploit the advantages of the “one-step” surgery and the advantages of the navigation represented by optimal choice of screws of higher dimensions with perfect fitting on the anatomy of the patient, associated with the reduced radiation exposure, the shortening of the surgical time and the greater accuracy. The system is particularly compact, it is included in a single container, therefore, reducing the cost of sterilization and management, optimizing the space necessary and the in the operating room for the nurse. The most innovative feature of this instrumentation is the type of screw, which has a particularly aggressive, self-threading tip that allows a very quick introduction of the screw; however, the system provides the introduction of the screw for the first step and thus, in case of small pedicles, an eventual correction of the trajectory may lead to a significant damage to the pedicle.

In literature we have found only one Viper Prime based studies but without navigation [\[10\]](#), and we found only one report about navigated one step technique [\[11\]](#) that present substantial differences with our study: it's a Medtronic navigation-based study, with the use of intraoperative image acquisition with O-arm, with consequent more costs; our study is based on preoperative CT scan with a modified use of

the software to improve navigation accuracy, without volumetric intraoperative image acquisition and sensitive cost reduction.

Kleck et al. [\[11\]](#) in their study reported the use of the Medtronic and DePuy instrumentation with handcrafted modifications to be used as one step as follows: Medtronic screwdriver with Solera screw and guide wire held 4–5 mm prominent with a Kocher (insets) and DePuy Expedium screwdriver with a SureTrak array attached to the screwdriver shaft. None of the instrumentation used was designed to be used for one step surgery as in our study.

4.5. Learning curve

The components of the learning curve include the ability to direct the instruments relying on images displayed on a screen, to replicate the maneuvers while positioning the instrumentation, as well as to adopt and develop an adequate technique while using the imaging-guided technology, but above all to understand when navigation is reliable and when to rely on X-ray or other techniques. The ability of surgeons to adapt to the use of this technology may depend on whether they grew up playing video games. Rosser et al. were able to correlate faster completion and reduced errors in laparoscopic interventions when surgeons had a background of over 3 h a week of video games [\[12\]](#).

5. Conclusions

Although CT image-guided navigation cannot replace the technical experience and the training of experienced surgeons, it may be considered a useful alternative to fluoroscopic free hands technique to increase accuracy, especially in complex surgical cases, in patients with altered anatomy, or in cases with poor fluoroscopic visualization as in thoracic levels and severe osteoporosis. The most significant advantage is the reduction of the need for intraoperative X-rays, the reduction of radiation exposure and the rate of misplacements and, consequently, the need for revision. The real cost of spinal navigation appears limited when compared to the clinical benefits offered. The use of intraoperative multiplanar fluoroscopic images or Intraoperative CT images in spine navigated instrumentation and fusion techniques appears to be intriguing in maximizing the efficacy and reducing the inaccuracy risks.

Declaration of Competing Interest

The authors declare that they have no known competing financial interests or personal relationships that could have appeared to influence the work reported in this paper.

Acknowledgement

We wish to thank Eng. Patrizia Boschetti, Eng. Claudio Aloisi and Dr. Serena Bradde for their statistical data support.

Declaration of patient consent: Patient's consent not required as patient's identity is not disclosed or compromised.

Funding support and sponsorship: This research did not receive any specific grant from funding agencies in the public, commercial, or not-for-profit sectors.

Ethics approval: There is no ethical issue in this paper.

Appendix A. Supplementary data

Supplementary data to this article can be found online at <https://doi.org/10.1016/j.inat.2020.100771>.

References

- [1] Roger Härtl, Khai Sing Lam, Jeffrey Wang, Andreas Korge, Frank Kandziora, Laurent Audigé, Worldwide Survey on the Use of Navigation in Spine Surgery, *World Neurosurgery*, 2013 Volume 79, Issue 1.
- [2] J.M. Hicks, A. Singla, F.H. Shen, Arlet V. Complications of Pedicle Screw Fixation in Scoliosis Surgery: A 430 Systematic Review, *Phila Pa 1976, Spine*, 2010, pp. 465–470.
- [3] V. Sarwahi, S.F. Wendolowski, R.C. Gecelter, et al., Are We Underestimating the Significance of Pedicle Screw Misplacement? *Phila Pa 1976, Spine*, 2016, p. 9.
- [4] F. Tian, L.Y. Tu, W.F. Gu, E.F. Zhang, Z.B. Wang, G. Chu, H. Ka, J. Zhao, Percutaneous versus open pedicle screw instrumentation in treatment of thoracic and lumbar spine fractures: A systematic review and meta-analysis, *Medicine (Baltimore)* 97 (41) (2018) e12535.
- [5] S. Vertuani, J. Nilsson, B. Borgman, et al., A cost-effectiveness analysis of minimally invasive versus open surgery techniques for lumbar spinal fusion in Italy and the United Kingdom, *Value Health* 18 (6) (2015) 810–816.
- [6] T. Laine, K. Mäkitalo, D. Schlenzka, K. Tallroth, M. Poussa, A. Alho, Accuracy of pedicle screw insertion: A prospective CT study in 30 low back patients, *Eur. Spine J.* 6 (6) (1997) 402–405.
- [7] T.E. Mroz, K.G. Abdullah, M.P. Steinmetz, et al., Radiation exposure to the surgeon during percutaneous pedicle screw placement, *Spinal Disord Tech.* (2011) p. 24: 264–7.
- [8] Radiation exposure to the surgeon and the patient during posterior lumbar spinal instrumentation: a prospective randomized comparison of navigated versus non-navigated freehand techniques. Villard J, Ryang YM, Demetriades AK, Reinke A, Behr M, Preuss A, Meyer B, Ringel F. *Spine (Phila Pa 1976)*, 2014; p. 39 (13): 1004-9.
- [9] K. Farah, P. Coudert, T. Graillon, B. Blondel, H. Dufour, O. Gille, S. Fuentes, Prospective comparative study in spine surgery between O-Arm and Airo systems: Efficacy and radiation exposure, *World Neurosurg.* 118 (2018 Oct) e175–e184.
- [10] A. Hiyama, D. Sakai, M. Sato, M. Watanabe, The analysis of percutaneous pedicle screw technique with guide wire-less in lateral decubitus position following extreme lateral interbody fusion, *J. Orthop. Surg. Res.* 14 (1) (2019) 304.
- [11] C.J. Kleck, C. Johnson, M. Akiyama, E.L. Burger, C.J. Cain, V.V. Patel, One-step minimally invasive pedicle screw instrumentation using O-arm and stealth navigation, *Clin. Spine Surg.* 31 (5) (2018 Jun) 197–202.
- [12] J.C. Rosser Jr, P.J. Lynch, L. Cuddihy, D.A. Gentile, J. Klonsky, R. Merrell, The impact of video games on training surgeons in the 21st century, *Arch. Surg.* 142 (2) (2007) 181–186.